



Thursday, August 12

[Visit our website](#)

[View Our Locations](#)

## A Message from Cardiology Associates, P.C.

---



Dear Colleagues,

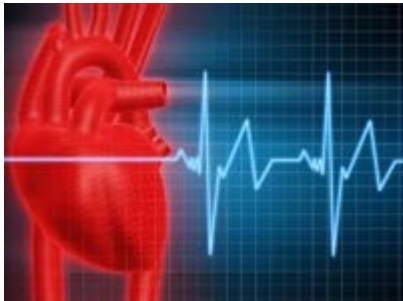Our August Referring Physician newsletter focuses on the diagnosis and treatment of atrial fibrillation. Atrial fibrillation (AF) is the most commonly diagnosed cardiac arrhythmia. Although it is not generally life-threatening, atrial fibrillation can result in bothersome symptoms and significant morbidity. Dr. Allison C. Warren presents and discusses two separate patient cases from symptoms through treatment options.

### About the Author

Dr. Allison C. Warren has been a member of Cardiology Associates, P.C. since 2005 and is board certified in Cardiology and Electrophysiology. She currently practices in Washington, D.C. and Maryland. Previously, she was an attending physician in Cardiology/Electrophysiology at Beth Israel Deaconess Medical Center in Boston, Massachusetts, as well as an instructor in Medicine at Harvard Medical School. Dr. Warren has published on a variety of topics in her field, including ablation of complex cardiac arrhythmias and evaluation of patients with disturbance of the cardiac rhythm.

## Evaluation of Atrial Fibrillation

---



### Presentation of Case A

- A 53-year-old woman was referred to our practice with paroxysmal palpitations. Palpitations had initially occurred almost two years earlier, but had been infrequent and relatively short lived.
- Recently, episodes of palpitations had become increasingly frequent and prolonged, occurring once or twice weekly, and lasting up to 8 hours in duration.
- The patient was very uncomfortable during episodes, and described a rapid irregular rhythm associated with dyspnea, fatigue, exercise intolerance and occasional lightheadedness.
- Past medical history was significant only for hypertension, which was well controlled on lisinopril 20 mg daily. There was a family history of atrial fibrillation: the patient's mother had paroxysmal atrial fibrillation beginning in her 60's, and a brother had persistent atrial fibrillation managed with warfarin and beta blockers. The patient denied history of snoring. She reported drinking a single 5-oz glass of wine daily.
- Physical examination was unremarkable. ECG demonstrated sinus rhythm at 58 BPM with evidence of left atrial abnormality. Labs, including a TSH, were within normal limits. An echocardiogram demonstrated normal LV and RV systolic function. The left atrium was at the upper limits of normal in size. There was evidence of early diastolic dysfunction. There was no significant valvular disease, and no evidence of pulmonary hypertension. It was felt very likely that the patient's symptoms were attributable to paroxysmal atrial fibrillation. The patient wore a looping event recorder, which demonstrated episodes of atrial fibrillation

with rapid ventricular response rate in the 120's - 140's.

- Risk factors for stroke included only hypertension. The patient was started on enteric coated aspirin 325 mg daily for stroke prophylaxis. As she was very bothered by episodes of atrial fibrillation, the decision was made to start antiarrhythmic medication. She was started on flecainide 100 mg twice daily, and on metoprolol XL 25 mg daily. She initially did very well on this combination of medications, and had no recurrence of atrial fibrillation over a period of 6 months.

- Approximately 6 months after beginning flecainide, she presented to Washington Hospital Center following a near syncopal event. She noted that she had experienced 2 brief episodes of palpitations over the week prior to this event. As episodes had lasted only 10-15 minutes, she had not sought medical attention for these.

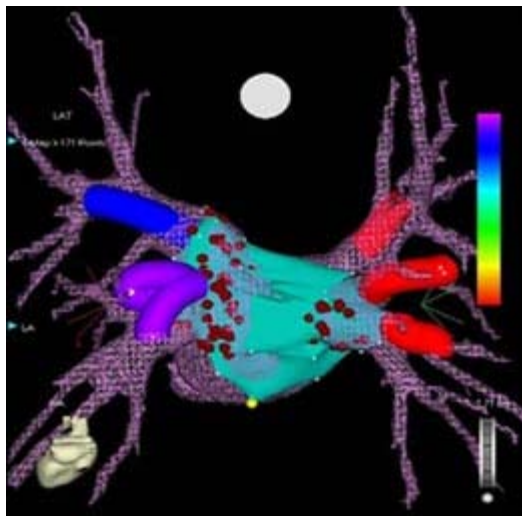
- Telemetry monitoring demonstrated a 20-minute episode of atrial fibrillation followed by a 6-second conversion pause prior to resumption of sinus rhythm at 60 BPM. Flecainide and metoprolol were discontinued. The decision was made to plan for ablation of atrial fibrillation.

- A cardiac MRI was performed to evaluate pulmonary venous anatomy. This demonstrated a mildly dilated LA, with 4 pulmonary veins in the normal positions. LV and RV function was normal. A few weeks later ablation of atrial fibrillation was performed. Images from the cardiac MRI were imported into the mapping system, and used to guide ablation. (See Figure 1) Ablation was performed around the four pulmonary veins, and electrical isolation of the veins was demonstrated. (See Figures 2A and 2B)

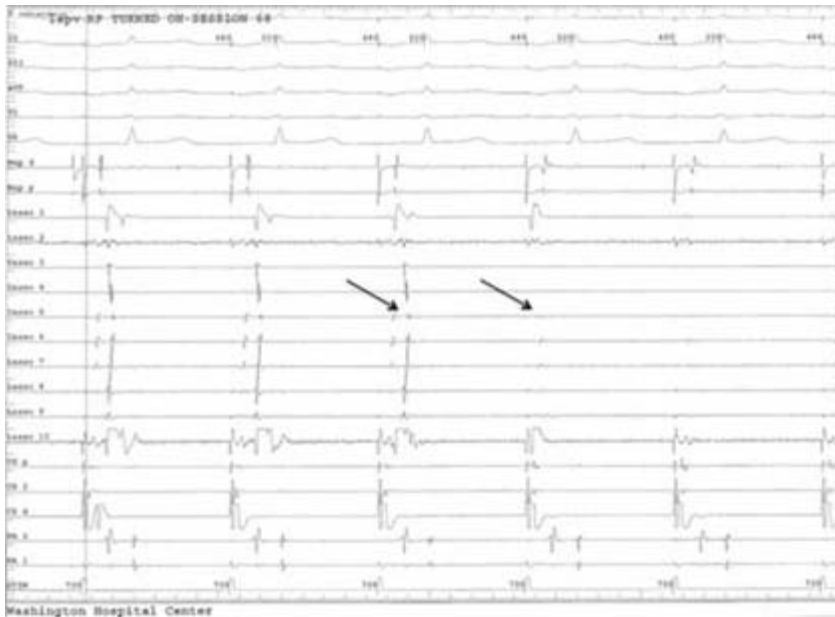
- Following pulmonary vein isolation, electrical stimulation resulted in induction of atrial flutter. Mapping revealed this to be Cavotricuspid isthmus dependent flutter, and Cavotricuspid isthmus ablation was performed. The patient was discharged on warfarin and low dose metoprolol.

- She experienced a brief recurrence of atrial fibrillation approximately 1 week after ablation. Metoprolol was discontinued 1 month after ablation, and warfarin was discontinued 3 months after ablation.

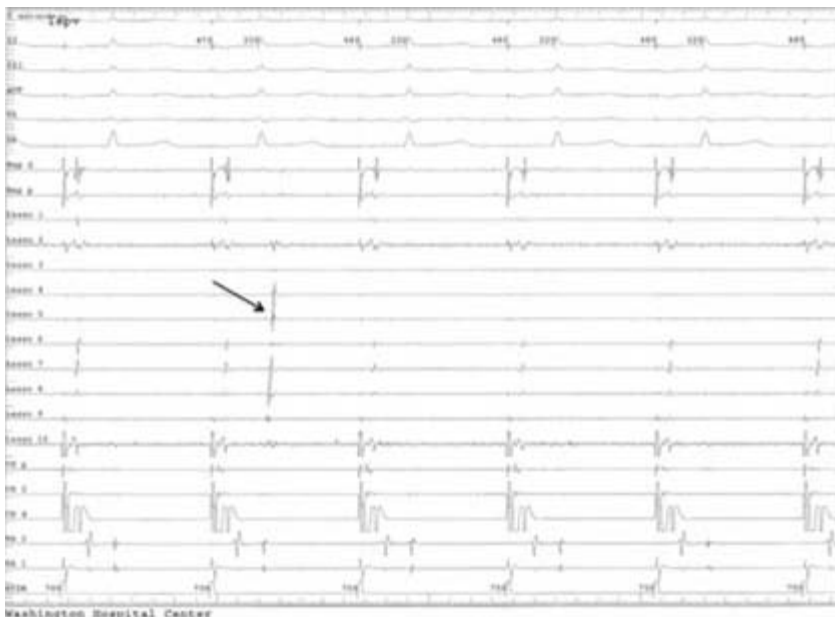
- The patient has done well over a period of 2 years since her ablation procedure. She has had no recurrent palpitations, and outpatient telemetry monitoring has demonstrated no asymptomatic atrial fibrillation or flutter. She has had no recurrent presyncope.



**FIGURE 1:** This figure demonstrates a CartoMerge map of the left atrium. The previously obtained left atrial image has been imported into the mapping system, and used to guide left atrial/pulmonary vein mapping. At the time of this image, ablation (indicated by maroon dots) has been performed around the LSPV, LIPV, and RIPV.



**Figure 2A**



**Figure 2B**

**FIGURE 2A** above demonstrates achievement of electrical isolation of the left superior pulmonary vein (LSPV) during ablation outside the vein. The Lasso catheter is placed just inside the LSPV. Pacing is being performed from the coronary sinus catheter (CS). On the left side of the tracing there is conduction into the LSPV. On the right side of the tracing LSPV signals are absent, indicating entrance block into the LSPV. **FIGURE 2B** demonstrates ongoing entrance block: pacing from the CS does not result in conduction into the vein. A spontaneous pulmonary vein potential is recorded (arrow).

### Presentation of Case B

- An 83-year-old gentleman with history of hypertension, sinus bradycardia, mitral valve prolapse and moderate mitral regurgitation had been followed by our practice over a period of 5 years for these issues.
- He was found to be in atrial fibrillation at the time of a routine follow up visit. He reported no symptoms attributable to atrial fibrillation. The ventricular response rate was controlled at rest, in the 60's.
- An echocardiogram demonstrated normal LV and RV systolic function. Mitral regurgitation was moderate, unchanged as compared to an echocardiogram performed 1 year earlier. There was evidence of mild pulmonary hypertension.

- Labs including TSH were normal.
- The patient admitted to drinking 3-4 alcoholic beverages daily, and was advised to decrease alcohol intake to 1 drink daily.
- He admitted to snoring on a regular basis, and was referred for a sleep study, which demonstrated moderate obstructive sleep apnea. He was started on CPAP.
- The patient was anticoagulated with warfarin for stroke prophylaxis. Discussion ensued with the patient and his family as to whether or not to make an attempt at restoration of sinus rhythm. The patient noted that his exercise tolerance had decreased as compared to a year earlier, but stated that he attributed this to his age.
- Eventually the decision was made to perform cardioversion after 1 month of therapeutic anticoagulation. Cardioversion was performed uneventfully. The rhythm following cardioversion was sinus in the 40's-50's.
- One month after cardioversion the patient reported that his exercise tolerance had clearly improved, and that his energy level had also improved.
- Three months after cardioversion the patient reported a consistently regular pulse. Warfarin was discontinued, and replaced with aspirin 325 mg daily. The patient has continued to monitor his pulse, and so far has remained in sinus rhythm.
- He has continued to use CPAP on a regular basis, and has continued to limit alcohol intake to 1 drink daily.

## Discussion

Atrial fibrillation (AF) is an increasingly prevalent problem in the United States. Approximately 2.3 million Americans are currently affected. It is not entirely clear why there has been rapid increase in prevalence of AF in this country, but increasing obesity has likely played a role. There are a variety of approaches to management of AF, with broad categories of management including rate control and rhythm control. Studies have been performed comparing these approaches, and rhythm control has not been shown to be superior to rate control. Atrial fibrillation is a complex disease, the pathophysiology of which is different in different patient populations. Our understanding of this pathophysiology is imperfect at best. Despite this we have had increasing success in curing atrial fibrillation in some patient populations over the past several years. Nonpharmacologic therapies including percutaneous ablation procedures and minimally invasive surgical procedures have proven particularly effective in curing paroxysmal AF. The literature suggests that approximately 70% of patients with paroxysmal AF can be cured with an initial ablation procedure. Of the remaining patients who are not cured with the initial procedure, approximately 70% can be cured with a second procedure. Persistent AF can also be cured by ablation, although the likelihood of success is less than that for paroxysmal AF, approximately 30-60% with an initial procedure depending on the duration of atrial fibrillation. Long-term persistent AF is harder to cure than short-term persistent AF, as progressive atrial remodeling occurs over time in AF. In most cases, an attempt at managing AF using antiarrhythmic medication should be undertaken prior to ablation due to procedural risk associated with this treatment.

Atrial fibrillation impacts patients very differently, and the approach to management of AF should be targeted to the individual patient. The cases above illustrate two very different patients, both of whom have clearly benefited from rhythm control. There are certainly patients who are truly asymptomatic in atrial fibrillation, and who do well with rate control. That being said, while large studies have not demonstrated clear benefit to maintenance of sinus rhythm over rate control, many individual patients benefit from a quality of life standpoint from being in sinus rhythm. In choosing a management strategy for an individual patient's atrial fibrillation, it is important to take into account a patient's symptoms, stroke risk, underlying heart disease, ability to tolerate anticoagulation, risk factors for AF and personal preference. Symptoms can be subtle, as with patient #2 above. Modifiable risk factors such as hypertension, alcohol intake and sleep apnea should be addressed. Finally, it is important to keep in mind that AF leads to electrical and structural atrial remodeling that tends to perpetuate AF, so that the longer a patient has been in AF, the more difficult restoration and maintenance of sinus rhythm become.

Our understanding of the pathophysiology of atrial fibrillation is improving, and hopefully over time improved understanding will provide us greater ability to effectively treat this complex disease.

## Please Join Our Mailing List

---

We are offering you this monthly newsletter as a way to provide cardiovascular news and update you on developments within our field. For your convenience, we are distributing our newsletter via e-mail. Visit our site at ([www.heartcapc.com](http://www.heartcapc.com)) and click the Referring Physician Newsletter link at the upper left corner of our home page. You will receive an e-Newsletter every month featuring an article or a case report from one of our physicians and links to other sources featuring new trends in the field of cardiology. Our focus will be on real questions and issues that we encounter in our day-to-day medical practice. In fact, if there is a topic that is of particular interest to you (or a question that is related to any of our articles) please e-mail your inquiries to our Project Manager, Nazar Snihur at [nsnihur@heartcapc.com](mailto:nsnihur@heartcapc.com). (Of course, we will not share your e-mail address outside of our offices.)

## Our Locations

---

### **Annapolis Cardiology Office**

2002 Medical Parkway, Suite 500  
Annapolis, MD 21401  
Phone: 410-573-6480  
Fax: 410-573-9413

### **Annapolis Vascular Office**

2002 Medical Parkway, Suite 520  
Annapolis, MD 21401  
Phone: 410-571-8430  
Fax: 410-573-5981

### **Bowie Office**

4175 N. Hanson Court  
Suite 100  
Bowie, MD 20716  
Phone: 301-809-6880  
Fax: 301-805-4233

### **Irving Street 4800N**

106 Irving Street, NW  
Suite 4800N  
Washington, DC 20010  
Phone: 202-726-5484  
Fax: 202-726-4587

### **Kent Island Office**

1630 Main Street  
Suite 208  
Chester, MD 21619  
Phone: 410-643-3186  
Fax: 410-643-4098

### **K Street Office**

2131 K Street, NW  
Suite 800  
Washington, DC 20037  
Phone: 202-822-9356  
Fax: 202-331-0451

### **Olney Office**

18109 Prince Philip Drive  
Suite 225  
Olney, MD 20832  
Phone: 301-774-5810  
Fax: 301-774-0188

You have received this message because your email address is part of our electronic mailing list. If you wish to be removed from our mailing list, please visit our [unsubscribe](#) page and enter your email address for removal from our system.